

Harumi Jyonouchi · Kenneth W. Lien ·  
Helen Aguila · Gaetano G. Spinnato ·  
Sanjeev Sabharwal · Beth A. Pletcher

## SAPHO osteomyelitis and sarcoid dermatitis in a patient with DiGeorge syndrome

Received: 22 August 2005 / Accepted: 7 December 2005 / Published online: 21 February 2006  
© Springer-Verlag 2006

**Abstract** We report the development and spontaneous resolution of annular erythematous skin lesions consistent with sarcoid dermatitis in a child with DiGeorge syndrome (DGS) carrying the 22q11.2 microdeletion. The skin lesion developed after she was treated with isoniazid (INH) following exposure to active tuberculosis (TB). After resolution of the skin lesions, this child developed sterile hyperplastic osteomyelitis consistent with SAPHO (synovitis, acne, pustulosis, hyperostosis, and osteitis) osteomyelitis in her right mandible triggered by an odontogenic infection. This child had congenital heart disease, dysmorphic facies, recurrent sinopulmonary infection, gastroesophageal reflux disease, scoliosis, reactive periostitis, and developmental delay. She had a low CD4 and CD8 T cell count with a normal 4/8 ratio, but normal cell proliferation and T cell cytokine production in response to mitogens. When she was presented with sterile osteomyelitis of right

mandible, she revealed polyclonal hypergammaglobulinemia with elevated erythrocyte sedimentation rate (ESR)/angiotensin converting enzyme (ACE) levels, but negative CRP. Autoimmune and sarcoidosis workup was negative. Inflammatory parameters gradually normalized following resolution of odontogenic infection and with the use of non-steroidal anti-inflammatory drugs (NSAIDs). The broad clinical spectrum of DGS is further expanded with the development of autoimmune and inflammatory complications later in life. This case suggests that patients with the DGS can present with unusual sterile inflammatory lesions triggered by environmental factors, further broadening the clinical spectrum of this syndrome.

**Keywords** DiGeorge syndrome · 22q11.2 deletion · Sarcoidosis · Sterile osteomyelitis · Immunodeficiency

**Abbreviations** ACE: Angiotensin converting enzyme · CRP: C reactive protein · DGS: DiGeorge syndrome · ESR: Erythrocyte sedimentation rate · NSAIDs: Nonsteroidal anti-inflammatory drugs · PPD: Purified protein derivative · SAPHO: (Synovitis, acne, pustulosis, hyperostosis, and osteitis) · TB: Tuberculosis

H. Jyonouchi (✉) · H. Aguila  
Division of Pulmonary, Allergy/Immunology, and  
Infectious Diseases, Department of Pediatrics,  
University of Medicine and Dentistry of New Jersey  
(UMDNJ)-New Jersey Medical School,  
185 South Orange Ave., F570A, MSB,  
Newark, NJ 07101-1709, USA  
e-mail: jyanouha@umdnj.edu

K. W. Lien  
Division of Allergy/Immunology, Department of Medicine,  
UMDNJ-New Jersey Medical School,  
Newark, NJ, USA

G. G. Spinnato  
Department of Oral and Maxillofacial Surgery,  
UMDNJ-New Jersey Medical School,  
Newark, NJ, USA

S. Sabharwal  
Department of Orthopedics,  
UMDNJ-New Jersey Medical school,  
Newark, NJ, USA

B. A. Pletcher  
Center for Human and Molecular Genetics,  
Department of Pediatrics, UMDNJ-New Jersey Dental School,  
Newark, NJ, USA

### Introduction

The most common features reported in patients with DiGeorge syndrome (DGS) are cardiac malformations, speech delay, and immunodeficiency secondary to thymic hypoplasia [26]. Although complete DGS patients suffer from severe T cell deficiency which requires thymic transplant [16, 17], in most DGS patients immunodeficiency is not fatal and may improve with age [3, 11, 22]. However, these patients appear to be still predisposed to complications commonly seen in patients with T cell dysfunction, including autoimmunity [11]. While about 9% of patients with DGS are reported to suffer from autoimmune conditions [2, 11, 15, 21], no specific autoimmune disease is associated with this syndrome. Instead, T cell dysfunction associated with DGS appears to increase the

risk of autoimmunity. That is, DSG patients are likely to develop dysregulated inflammatory responses to various environmental stimuli secondary to T cell dysfunction, which could evolve into autoimmune diseases. We describe here the development of transient skin lesions consistent with sarcoid dermatitis following exposure to tuberculosis (TB)/ isoniazid (INH) treatment and SAPHO (Synovitis, acne, pustulosis, hyperostosis, and osteitis) osteomyelitis triggered by odontogenic infection in a child with DGS.

## Case report

A 12-year-old African-American girl presented to the Pediatric Allergy and Immunology Clinic for evaluation of possible sarcoidosis with concurrent SAPHO osteomyelitis of her right mandible. She also complained of bilateral ankle and knee joint aches without synovitis. At her initial visit, positive physical findings included a significantly swollen right proximal mandible along with right mandibular hypertrophy. Facial dysmorphism typical for DGS was apparent, including a prominent nasal root and small palpebras. She was also noted to have small hands and tapered fingers. She is developmentally delayed, with a major delay in speech.

Her past medical history is significant for multiple illnesses since infancy. She had a congenital heart defect (Tetralogy of Fallot), and the first surgical repair at 1 year of age was complicated by cardiac arrest, failure to thrive requiring gastric tube feeding, and other complications. The second surgery was performed at age 2 years without an event. She also had a gastroesophageal reflux disease requiring Nissen fundoplication at age 2 years. Immuno-deficiency was indicated by numerous sino-pulmonary infection and frequent Staphylococcal skin infection (cellulitis and impetigo) in her infancy and early childhood. However, sino-pulmonary infection has become less frequent over the past 2–3 years, and no skin infection has been documented after 5 years of age. She also suffers from asthma, with sinusitis being a major trigger. At age 9 years she was diagnosed with seizure disorder secondary to grand mal seizures and electroencephalogram (EEG)-documented epileptiform activity; she had seizures with normal serum Ca levels and has been treated with valproic acid. She also suffers from scoliosis in the form of 33° right angle thoraco-lumbar (T10–L2) scoliosis, requiring a brace.

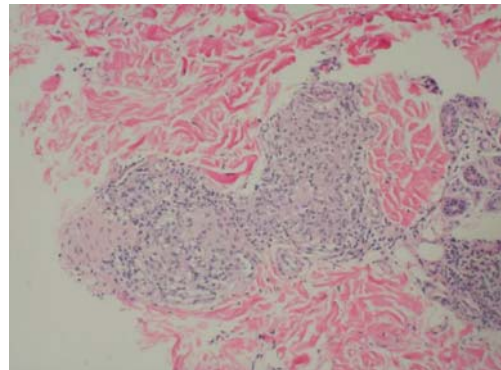
In addition to these clinical features commonly seen in DGS patients, she also has developed sterile skin and bone lesions during the recent 3 years. At age 9 years, she had a positive reactivity to a purified protein derivative (PPD) with a negative chest X-ray. She was likely exposed to active TB through her father, who was diagnosed with AIDS. She was treated with INH for 9 months. Following TB treatment, annular erythematous skin lesions developed on her left leg. These lesions were histologically consistent with sarcoid dermatitis (Fig. 1). Her skin lesions resolved spontaneously without treatment over the next few months. She also developed recurrent biopsy-proven reactive

periostitis localized to the left tibia during 10–11 years of age. These lesions occurred adjacent to the location of the previous sarcoid-like skin lesions. At age 12 years, she developed right mandibular swelling triggered by dental abscesses. She underwent root canal procedures, and the biopsy specimen revealed sterile hypertrophic osteomyelitis (SAPHO osteomyelitis) [24].

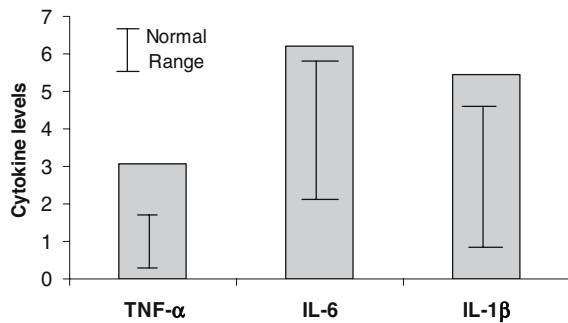
Her family history is significant for a father who died of AIDS and a mother who was diagnosed with breast cancer. HIV ELISA was non-reactive in both the patient and her mother. The patient has a typically growing, healthy older sister.

The results of the initial immune workup were significant for polyclonal hypergammaglobulinemia and elevated erythrocyte sedimentation rate (ESR: IgG, 2640 [normal range (N): 691–1618]; IgA, 667 (N: 70–380); IgM, 102 (N: 60–265); IgE, 129 (N: 0–200); ESR, 40 (N: 0–20). She was negative for rheumatoid factor, ANA, lupus anti-coagulant, and anti-cardiolipin antibodies, with normal coagulation studies on several occasions giving persistently negative C reactive protein (CRP). An immune workup also revealed low CD4 and CD8 T cell numbers: CD8<sup>+</sup> T cells, 212 (N: 262–1066); CD4<sup>+</sup> T cells, 516 (N: 689–1566); CD19<sup>+</sup> B cells, 635 (N: 90–543); CD16<sup>+</sup>CD56<sup>+</sup> natural killer cells, 511 (N: 102–582). Fluorescence in situ hybridization (FISH) analysis revealed monosomic deletion of chromosome 22q11.2, thereby confirming the diagnosis of DGS. Her peripheral blood mononuclear cells (PBMCs) revealed normal proliferative responses and the production of T cell cytokines (IFN- $\gamma$  and IL-5) in response to T cell mitogens (concanavalin A and phytohemagglutinin). However, her PBMCs produced a greater than normal range of tumor necrosis factor- $\alpha$  (TNF- $\alpha$ ), interleukin (IL)-6, and IL-1 $\beta$  with lipopolysaccharide (LPS; endotoxin) even when cells were obtained while she was free from acute inflammation (Fig. 2). The methodologies of cytokine production assays are described elsewhere [12, 13].

The Workup for systemic sarcoidosis was negative with a normal Ga scan, negative 24-h urine Ca, negative serum TNF- $\alpha$ , persistently normal serum Ca levels, normal chest computed tomography (CT), and slightly elevated angiotensin-converting enzyme (ACE) levels in the serum (100,



**Fig. 1** Histology of skin punch biopsy specimen from the patient's left leg (HE staining). Findings were consistent with sarcoid dermatitis. Periodic acid Schiff (PAS), Gomori's methanamine silver (GMS), and acid fast stains were negative for organisms



**Fig. 2** TNF- $\alpha$ , IL-6, and IL-1 $\beta$  production by PBMCs obtained from this patient. PBMCs were stimulated with lipopolysaccharide (0.1  $\mu$ g/ml) overnight, and cytokine levels in the supernatant were measured [11, 12]. Reference values were obtained from 12 normal control children (Median age: 8.3 years). Y-axis scale: nanograms per milliliter for TNF- $\alpha$ ; and IL-1 $\beta$ ;  $\times 10$  nanograms per milliliter for IL-6

with N: 6–89). Given the negative workup for sarcoidosis and evidence of persistent sterile inflammation, we elected to treat her with nonsteroidal anti-inflammatory drugs (NSAIDs). Her knee joint ache and facial swelling almost resolved 1 month after this treatment, but her left knee arthralgia recurred when NSAIDs were discontinued. Her ESR, Ig levels, and ACE levels were all normalized over a 6- to 12-month period of time after starting the NSAIDs treatment. She has developed transient thrombocytopenia (70,000/mm<sup>3</sup>) following acute sinusitis, but her platelet count normalized within 4 weeks after resolution of the sinusitis.

## Discussion

DGS patients are generally characterized by at least three out of four features: congenital heart defect, facial dysmorphism, hypocalcemia, and evidence of thymic hypoplasia [26]. Most DGS patients have monosomic deletions of chromosome 22q11.2 [21, 27], which is one of the most common chromosomal disorders, occurring in 1 of 3000–6000 children [7, 10, 20, 25]. Due to variable degrees of thymic hypoplasia, DGS patients present a wide variety of clinical symptoms associated with T cell dysfunction. The patient described here presents clinical features not previously described in DGS (sarcoid dermatitis and SAPHO osteomyelitis), further widening clinical spectrum of this syndrome.

Sarcoidosis, a granulomatous disease, is thought to be a product of aberrant immune inflammatory responses to environmental factors (most likely microbes) in a person with a genetic predisposition. Indirect evidence suggests a role of microorganisms as a source of antigenic stimuli in development of sarcoidosis in genetically susceptible individuals [8]. Key cellular players in sarcoid inflammation include type 1 T (Th1) cells and macrophages with an increase in the production of Th1 cytokines [IL-2 and interferon- $\gamma$  (IFN- $\gamma$ )] and inflammatory cytokines produced by macrophage-monocyte lineage cells (IL-1, TNF- $\alpha$ , IL-12, IL-18, various chemokines) [29].

Not surprisingly, sarcoid-like granulomatous lesions are frequently reported in patients with T cell dysfunction, secondary to aberrant inflammatory responses associated with T cell dysfunction. For example, HIV patients and patients with common variable immunodeficiency (CVID) are known to present with a variety of sterile inflammatory and/or autoimmune conditions, paradoxically requiring treatments with immunomodulating or immunosuppressive agents [5, 6, 28]. Both HIV and CVID patients can develop granulomatous diseases [18], and their histological findings are often consistent with sarcoidosis [9, 14, 19].

However, sarcoidosis or sarcoid-like lesions have not been described in DGS. This might be partly attributed to atypical clinical manifestations as observed in our patient who developed a sarcoid-like skin lesion on the left leg following TB treatment with INH. The patient had positive PPD reactivity (>10 mm) with a negative chest X-ray, indicating that she has intact delayed type T cell reactivity as opposed to negative PPD reactivity typically seen in sarcoidosis patients. During the same period, she also developed reactive periostitis in the bone adjacent to the skin lesion. These findings indicate that TB exposure and/or INH treatment may have triggered aberrant granulomatous inflammation in the skin and possibly in the bone due to T cell dysfunction associated with DGS.

A year later, she developed sterile hyperplastic osteomyelitis of the right mandible triggered by an odontogenic infection, revealing hypergammaglobulinemia, elevated ESR, and slightly elevated ACE levels. Histological findings are consistent with Garré or SAPHO osteomyelitis [1, 23, 24]. In her case, these bony changes are also likely to be associated with aberrant inflammatory responses triggered by the odontogenic infection. Non-pus producing hyper-proliferative bony lesions might suggest a role of T cells in the pathogenesis, since T cells responding to localized antigenic stimuli can trigger such bone inflammation. The presented case also revealed unusual clinical features, including persistent painful swelling of the right mandible and prolonged elevation of inflammatory parameters, even after successful periodontal surgery. Her excellent responses to NSAIDs indicate that her condition may be consistent with chronic recurrent multifocal osteomyelitis [4] or SAPHO syndrome [1, 24]. However, her clinical features lack skin manifestation (acne, pustulosis, and psoriasis), joint symptoms (arthritis or synovitis), or multifocal osteitis or osteomyelitis.

It is of note that her monocyte lineage cells produced excessive amounts of proinflammatory cytokines with LPS, a surrogate stimulant of innate immunity, although her cells revealed normal T cell cytokine production with mitogens. We may speculate that repeated microbial stimuli led to over-activation of her innate immune cells secondary to T cell immunodeficiency associated with DGS, thereby contributing to her unusual clinical features.

In summary, the presented case illustrates unusual inflammatory responses in a DGS patient with monosomic deletion of chromosome 22q11.2, further broadening the clinical spectrum of immunodeficiency associated with this syndrome.

## References

- Beretta-Piccoli BC, Sauvain MJ, Gal I, Schibler A, Saurenmann T, Kressebuch H, Biancetti MG (2000) Synovitis, acne, pustulosis, hyperostosis, osteitis (SAPHO) syndrome in childhood: a report of ten cases and review of the literature. *Eur J Pediatr* 159:594–601
- Bruno B, Barbier C, Lambilliotte A, Rey C, Turck D (2002) Auto-immune pancytopenia in a child with DiGeorge syndrome. *Eur J Pediatr* 161:390–392
- Chinen J, Rosenblatt HM, Smith EO, Shearer WT, Noroski LM (2003) Long-term assessment of T-cell population in DiGeorge syndrome. *J Allergy Clin Immunol* 111:573–579
- Chun CS (2004) Chronic recurrent multifocal osteomyelitis of the spine and mandible: case report and review of the literature. *Pediatrics* 113:e380–e384
- Cunningham-Rundles C (2001) Common variable immunodeficiency. *Curr Allergy Asthma Rep* 1:421–429
- Cunningham-Rundles C, Bodian C (1999) Common variable immunodeficiency: clinical and immunological features of 248 patients. *Clin Immunol* 92:34–48
- Devriendt K, Fryns JP, Mortier G, Van Thienen MN, Keymolen K (1998) The annual incidence of DiGeorge/velocardiofacial syndrome. *J Med Genet* 35:789–790
- Du Bois RM, Goh N, McGrath D, Cullinan P (2003) Is there a role for microorganisms in the pathogenesis of sarcoidosis? *J Int Med* 253:4–17
- Foulon G, Wislez M, Maccache JM, Blanc FX, Rabbat A, IsraelBiet D, Valeyre D, Mayaud C, Cadranel J (2004) Sarcoidosis in HIV-infected patients in the era of highly active antiretroviral therapy. *Clin Infect Dis* 38:418–425
- Goodship J, Gross I, LiLing J, Wren C (1998) A population study of chromosome 22q11 deletions in infancy. *Arch Dis Child* 79:348–351
- Jawad AF, McDonald-McGinn DM, Zackai E, Sullivan KE (2001) Immunologic features of chromosome 22q11.2 deletion syndrome (DiGeorge syndrome/velocardiofacial syndrome). *J Pediatr* 139:715–723
- Jyonouchi H, Sun S, Kelly A, Rimell FL (2003) The effects of exogenous interferon- $\gamma$  (IFN- $\gamma$ ) on patients with treatment-resistant chronic rhinosinusitis and dysregulated IFN- $\gamma$  production - A pilot study. *Arch Otolaryngol Head Neck Surg* 129:563–569
- Jyonouchi H, Geng L, Ruby A, Zimmerman-Bier B (2005) Dysregulated innate immune responses in young children with autism spectrum disorders (ASD): their relationship to gastrointestinal (GI) symptoms and dietary intervention. *Neuropsychobiology* 51:77–85
- Kanathur N, Byrd RP Jr, Fields CL, Roy TM (2000) Noncaseating granulomatous disease in common variable immunodeficiency. *South Med J* 93:631–633
- Kawame H, Adachi M, Tachibana K, Kurosawa K, Ito F, Gleason MM, Weinimer S, Levitt-Katx L, Sullivan K, McDonald-McGinn DM (2001) Graves' disease in patients with 22q11.2 deletion. *J Pediatr* 139:892–895
- Markert ML, Sarzotti M, Ozaki DA, Sempowski GD, Rhein ME, Hale LP, Buckley RH, Le Deist F, Alexieff MJ, Li J, Hauser ER, Haynes BF, Rice HE, Skinner MA, Mahaffey SM, Jagers J, Stein LD, Mill MR (2003) Thymus transplantation in complete DiGeorge syndrome: immunologic and safety evaluations in 12 patients. *Blood* 102:1121–1130
- Markert ML, Alexieff MJ, Li J, Sarzotti M, Ozaki DA, Devlin BH, Sedlak DA, Sempowski GD, Hale LP, Rice HE, Mahaffey SM, Skinner MA (2004) Complete DiGeorge syndrome: development of rash, lymphadenopathy, and oligoclonal T cells in 5 cases. *J Allergy Clin Immunol* 113:734–741
- Mechanic LJ, Dikman S, Cunningham-Rundles C (1997) Granulomatous disease in common variable immunodeficiency. *Ann Intern Med* 127:613–617
- Morris DG, Jasmer RM, Huang L, Gotway MB, Nishimura S, King TE Jr (2003) Sarcoidosis following HIV infection: evidence for CD4<sup>+</sup> lymphocyte dependence. *Chest* 124:929–935
- Oskarsdottir S, Vujic M, Fasth A (2004) Incidence and prevalence of the 22q11 microdeletion syndrome: a population-based study in Western Sweden. *Arch Dis Child* 89:148–151
- Perez E, Sullivan KE (2002) Chromosome 22q11.2 deletion syndrome (DiGeorge and velocardiofacial syndromes). *Curr Opin Pediatr* 14:678–683
- Pillero LM, Sanford AN, McDonald-McGinn DM, Zackai EH, Sullivan KE (2004) T-cell homeostasis in humans with thymic hypoplasia due to chromosome 22q11.2 deletion syndrome. *Blood* 103:1020–1025
- Segev E, Hayek S, Lokiec F, Ezra E, Issakov J, Wientroub S (2001) Primary chronic sclerosing (Garre's) osteomyelitis in children. *J Pediatr Orthop B* 10:360–364
- Suei Y, Taguchi A, Tanimoto K (2005) Diagnosis and classification of mandibular osteomyelitis. *Oral Surg Oral Med O* 100:207–214
- Tezenas Du Montcel S, Mendizabai H, Ayme S, Levy A, Phillip N (1996) Prevalence of 22q11 microdeletion. *J Med Genet* 33:719
- Wilson DI, Burn J, Scambler P, Goodship J (1993) DiGeorge syndrome: part of CATCH 22. *J Med Genet* 20:852–856
- Yamagishi H, Srivastava D (2003) Unraveling the genetic and developmental mysteries of 22q11 deletion syndrome. *Trends Mol Med* 9:383–389
- Zandman-Goddard G, Shoenfeld Y (2002) HIV and autoimmunity. *Autoimmune Rev* 6:329–337
- Ziegenhagen MW, Müller-Quernheim J (2003) The cytokine network in sarcoidosis and its clinical relevance. *J Int Med* 253:18–30